



**PRESENTING CLINICAL SIGNS**

**DATE** History: Grade III/VI murmur. FIV+. Pre-anesthetic evaluation (dental). BNP WNL.

**7/6/23** **ECHOCARDIOGRAPHIC FINDINGS**  
2D, M-mode, and Doppler study.

**PERFORMED BY:** Left atrial size is normal. The mitral valve is normal. Left ventricular wall thickness is normal. Left ventricular internal dimensions are normal. Left ventricular systolic function is hyperdynamic. The aorta and aortic valve appear normal, though there is mildly increased flow velocity in the ascending aorta. Right atrial and right ventricular dimensions are normal. The tricuspid valve is normal. The pulmonary artery and pulmonic valve are normal. No shunting lesions are visualized. No pericardial effusion or cardiac masses are seen. Pleural effusion is present.

Kelly Vazquez

**INTERPRETED BY**

Keith Blass, DVM,  
MS, DACVIM  
(Cardiology)

LA/Ao – 1.31  
IVSd – 4.1 mm  
LVPWd – 3.7 mm  
LVIDd – 17.1 mm  
LVIDs – 6.8 mm  
FS – 60%  
LVOT – 1.58 m/s  
RVOT – 1.04 m/s

**PATIENT**

Cookie Pryor

**SPECIES** **ASSESSMENT/RECOMMENDATIONS**  
Normal echocardiogram

Feline

This examination demonstrates no evidence of structural heart disease. Cookie's murmur appears to be due to the presence of mildly increased flow velocity in his aorta, which is a common reason for a functional/innocent murmur to develop in cats.

**BREED**

DSH

Cookie's cardiovascular risk for general anesthesia is low based on this exam, and there are no contraindications to the use of any specific anesthetic agents.

**SEX**

No therapy is recommended based on this exam.

**MN**

A recheck echocardiogram is recommended if the characteristics of Cookie's murmur change, or if other new physical exam and/or clinical abnormalities suggestive of cardiac dysfunction develop.

**AGE**

10 y

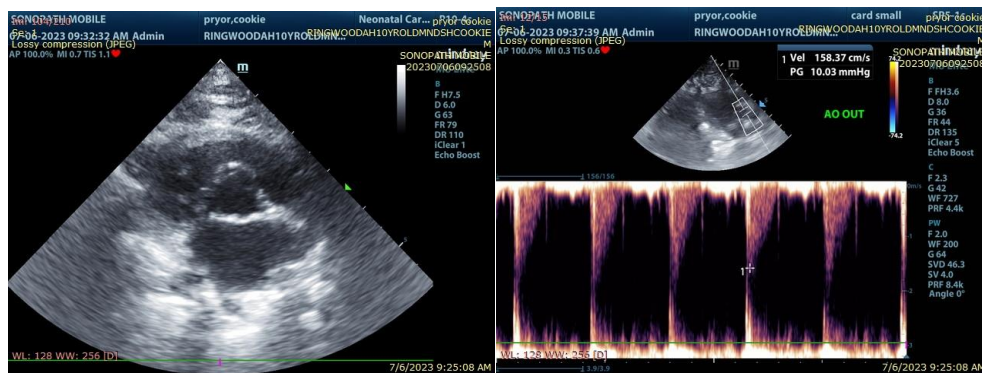
**WEIGHT**

**HOSPITAL NAME**

Ringwood AH

**REFERRING VET**

Dr. Walker





The information and recommendations provided are based on the images presented by the referring veterinarian. No evaluation can be communicated regarding pathology that was not visible in the image/video clips provided.

**DATE**

7/6/23

Thank you for this referral. If the clinical or image interpretation does not parallel your findings or if I can be of any further assistance please contact me.

**PERFORMED BY:**

Kelly Vazquez

**Keith Blass, DVM, MS, DACVIM (Cardiology)**  
KeithBlass@gmail.com  
631-804-5754

**INTERPRETED BY**

Keith Blass, DVM,  
MS, DACVIM  
(Cardiology)

**PATIENT**

Cookie Pryor

**SPECIES**

Feline

**BREED**

DSH

**SEX**

MN

**AGE**

10 y

**WEIGHT**

**HOSPITAL NAME**

Ringwood AH

**REFERRING VET**

Dr. Walker